

*Research Article*

## The Role of Peroneal Artery Pedicled Perforator Flap for Reconstruction of Lower Leg and Foot Soft Tissue Defects.

Mohamed G. Sayed Saleh, Khalid M. Hassan, Mohamed K. Alla Kamel, and Doaa A. Zaghoul.

Department of General Surgery, El-minia Faculty of Medicine

### Abstract

**Introduction:** Reconstruction of lower leg and foot soft tissue defects remain a challenging task, particularly in patients with circulation problems. Various options including local flaps, free flaps, and muscle flaps have been used for reconstruction in these cases (Sargent, 2017)

**Aim of the study:** The aim of this study is to Evaluate the role of peroneal artery pedicled perforator flap for reconstruction of lower leg and foot soft tissue defects.

**Materials & Methods:** Study design with a prospective non randomized clinical study, it has been conducted in the Plastic surgery unit Minia university hospital in the period from January to August 2019. It included 20 patients presented with raw areas in the lower leg, ankle and foot.

**Results:** The flap survival was excellent in middle age patients with small defect but the flap survival was bad in young age patients with large defect. **Discussion:** The age of the patient and the surface area of the defect play an important role in flap survival. **Recommendation:** based on the current study we recommend that the peroneal artery pedicled perforator flap has good results in small to medium sized defects and not large defects.

**Keywords:** Peroneal artery, Perforator flap, Reconstruction.

### Introduction

Perforator based flaps are constituted by areas of cutaneous and subcutaneous tissue nourished by perforator branches originating from deep vascular axis with an intramuscular [musculocutaneous perforator flap (MCPF)] or an intraseptal course [septocutaneous perforator flap (SCPF)]. A single perforator vessel may nourish a large fasciocutaneous area, even in sites considered unreachable or at risk for local flap as the inferior third of the leg and ankle. (Blondeel et al., 2013)

### Patient & Methods

Study design with a prospective non randomized clinical study, it has been conducted in the Plastic surgery unit Minia university hospital in the period from

January to August 2019. It included 20 patients presented with raw areas in the lower leg, ankle and foot.

### Inclusion criteria:

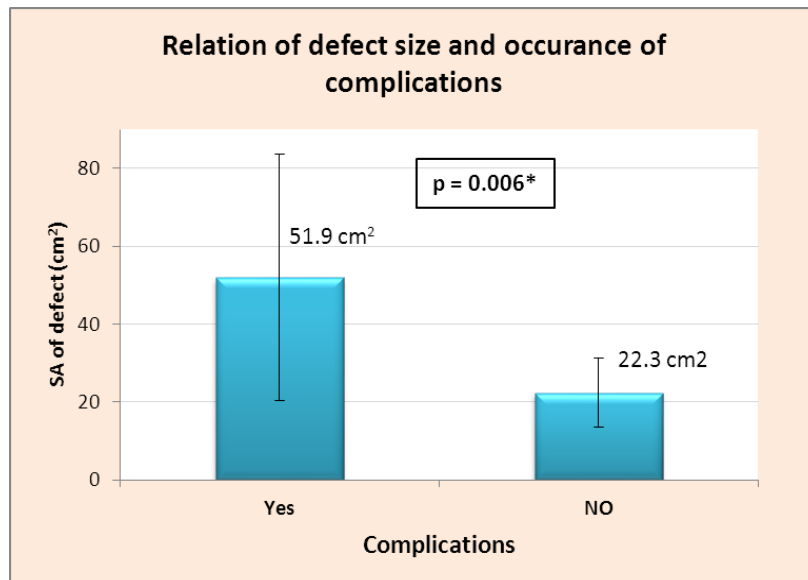
- All ages and both sexes.
- Small and large defects.
- Acute and chronic defects.
- Diabetic and non-diabetic patients

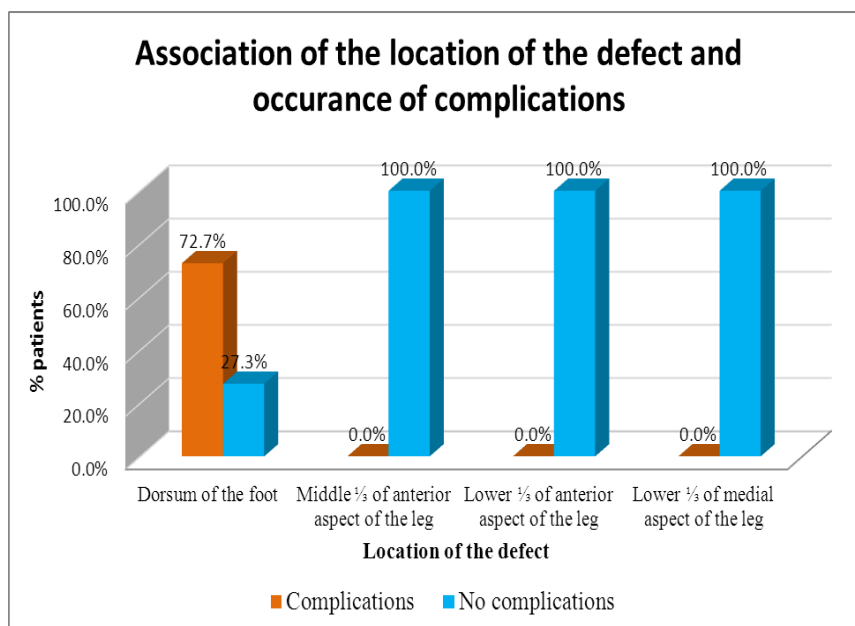
### Exclusion criteria:

- Patients with chronic ischemia or chronic venous insufficiency
- Chronic heavy Smokers.
- Cases associated with arterial injury or hematological disorders.
- Presence of scarred tissue at the pedicle or concomitant other serious injuries

**Results**

	Complications		p value
	Yes (n=8)	No (n=12)	
Age			0.140
Mean ± SD	18.1±11.8	30.1±19.6	
(Range)	(7-37)	(10-65)	
Surface are of defect (cm <sup>2</sup> )			0.006*
Mean ± SD	51.9±31.6	22.3±8.9	
(Range)	(15-98)	(12-40)	
Location of defect			0.003*
Dorsum of the foot	8 (72.7%)	3 (27.3%)	
Middle 1/3 of anterior aspect of the leg	0 (0%)	3 (100%)	
Lower 1/3 of anterior aspect of the leg	0 (0%)	3 (100%)	
Lower 1/3 of medial aspect of the leg	0 (0%)	3 (100%)	0.004*
Re-operation			
Yes	5 (62.5%)	0 (0%)	
No	3 (37.5%)	12 (100%)	





### Discussion

One single perforator vessel located in an eccentric position in relation to a skin paddle may support a large skin area thanks to the opening of potential vascular territories, which move to the peripheral border of the flap. The process of vascular adoption is promoted by the increase of blood pressure, which occurs in the perforator artery after closure of subcutaneous and intramuscular branches during flap harvesting (Georgescu, 2012).

(Karki and Narayan, 2012) has described the principles for lower-limb reconstruction with perforator local flap meticulously step-by-step. In particular, this author pointed out the importance of these flaps in covering medial and lateral malleolar areas and of the heel and Achilles tendon. Defects in these anatomical areas, although often small, are usually difficult to treat with alternative non perforator local flaps. The value of perforator local flaps is further increased by the optimal quality of tissues transferred for defect reconstruction.

In our study no case was diabetic; 7 cases were smokers (35%), complication occurred in 8 cases (40%), the complications ranged from partial loss in 6 cases (30%) to complete flap loss in 2 cases (10%), the complete flap loss were due to

venous congestion, the cases which had partial flap loss or partial flap necrosis (partial flap survival) 6 cases (2 of them were due to partial ischemia, 4 of them due to venous congestion).

In our study the complication occurred in 8 cases (40%), 2(10%) of them were due to arterial ischemia, the other 6(30%) cases were due to venous congestion.

In our study the location of the defect played an important role in flap survival, as all the complicated cases the defect was located at the dorsum of the foot.

Also, the surface area or the defect size affect the flap outcome, as the complication occurred in flaps which were harvested to cover recipient sites with large surface areas

In our study the 2 patients who had complete flap loss are located at the dorsum of the foot and were children as they were 7 years old and 9 years old.

In our study 5 cases needed other surgical sessions, the 2 cases that had complete flap loss needed multiple sessions of debridement and coverage of the raw area by STSG after granulation tissue has been formed. The other 3 cases that needed another surgical session, was only for

debridement of the distal necrosed part and it was left to heal by secondary intention.

In our study the operation time ranged from (90-120) minute with mean of the operation time was 105 minutes.

In our study all the donor site was closed by STSG.

(Cheng et al., 2017) stated that from May 1997 to September 2015, 55 peroneal artery perforator flaps were performed in patients with chronic lower extremity wounds, 7 patients had DM (diabetes mellitus), 4 patients had hypertension (HTN), and 4 patients had arteriopathy.

(Cheng et al., 2017) identified the following risk factors: age older than 60 years, diabetes and arteriopathy play an important role in flap necrosis which represent 10 cases (18.2%), all 10 cases had smoking histories so the smoking play an important role in flap complication or flap necrosis.

#### **Conclusion & Recommendations**

From the previous studies we found that the leg has always been known for poor wound healing, so surgeons had few reconstructive options to reconstruct leg defects.

Perforator flaps are safe and reliable flaps and represent an important step forward in reconstructive plastic surgery of the leg as they (1) decrease donor-site morbidity, preserving muscles and their functions and sparing the main vascular trunks; (2) specificity in "like-to-like" soft tissue replacement; (3) a better cosmetic and reconstructive result.

#### **References**

1. Blondeel PN, Morris SF, Hallock GG and Neligan PC. (2013) Perforator flaps: anatomy, technique, & clinical applications: CRC Press.
2. Cheng L, Yang X, Chen T and Li Z. (2017) Peroneal artery perforator flap for the treatment of chronic lower extremity wounds. *Journal of orthopaedic surgery and research* 12: 170.
3. Georgescu AV. (2012) Propeller perforator flaps in distal lower leg: evolution and clinical applications. *Archives of plastic surgery* 39: 94.
4. Karki D and Narayan R. (2012) The versatility of perforator-based propeller flap for reconstruction of distal leg and ankle defects. *Plastic surgery international* 2012.